

Therapeutic strategies for nerve injuries: current findings and future perspectives. Are textile technologies a potential solution?

DOI: 10.35530/IT.073.06.2021115

CRISTIAN VLADIMIR VANCEA
ANDREEA GROSU-BULARDA
ANDREI CRETU
FLORIN-VLAD HODEA
KHALID AL-FALAH
ALEXANDRU STOIAN

ALEXANDRU LAURENTIU CHIOTOROIU
CARMEN MIHAI
CRISTIAN SORIN HARIGA
IOAN LASCĂR
RĂZVAN NICOLAE TEODOREANU

ABSTRACT – REZUMAT

Therapeutic strategies for nerve injuries: current findings and future perspectives. Are textile technologies a potential solution?

Peripheral nerve lesions represent debilitating conditions that determine sensitive, motor and associated psychosocial losses, deeply and severely affecting the quality of life. Despite adequate microsurgical repair, functional results are variable and often dissatisfying.

This study aimed to analyse and discuss peripheral nerve lesion cases from our clinic, involving the upper limb, an anatomical segment with impactful functional importance. We followed the distribution of nerve lesions throughout a three-year period, describing the patients' characteristics and the therapeutic protocols. Furthermore, we reviewed the relevant literature to identify potential therapeutic strategies that may help optimize functional results.

In the presented clinical study, most of the patients benefited from direct microsurgical repair of the nerve injury. However, we had a series of cases of nerve defects that could not be approached with primary repair. When a nerve cannot be repaired by direct neurorrhaphy, there are different options for bridging the nerve gap, each with its indications and advantages. Autografts still represent the gold standard in treating nerve gaps, but other procedures, such as vascularized nerve grafting, nerve conduits, allografts and nerve transfers, can be successfully used in some cases. The current focus in the field is the development of nerve conduits. Textile technologies represent a promising field in creating nerve conduits, given the ease of the manufacturing process, the affordable production cost and good mechanical properties.

Keywords: peripheral nerve injury, nerve gap, graft, nerve conduits, textile technologies

Strategii terapeutice în leziunile nervoase: abordările actuale și direcții viitoare. Reprezintă tehnologia textilă o soluție fezabilă?

Leziunile nervilor periferici reprezintă condiții debilitante care determină disfuncții senzitive, motorii și psihosociale, afectând profund și sever calitatea vieții. În ciuda unei rezolvări microchirurgicale adecvate, rezultatele funcționale sunt variabile și, frecvent, nesatisfăcătoare.

Scopul acestui studiu a fost să analizeze și să discute cazurile de leziuni nervoase periferice din clinica noastră, implicând membrul superior, un segment anatomic cu impact funcțional important. Am urmărit distribuția leziunilor nervoase pe o perioadă de trei ani, prezentând caracteristicile pacienților și protocolul terapeutic. În afară de aceasta, am analizat literatura de specialitate cu scopul de a identifica potențiale strategii terapeutice care ar putea fi utile în a optimiza rezultatele funcționale.

În studiul clinic prezentat, majoritatea pacienților au beneficiat de sutura directă microchirurgicală a leziunii nervoase. Cu toate acestea, am avut o serie de cazuri prezentând defect nervos care nu au putut fi reparate prin sutură primară. Când o leziune nervoasă nu poate fi rezolvată prin sutură directă, există diferite opțiuni pentru a repara defectul nervos, fiecare cu propriile indicații și avantaje. Autogrefele reprezintă încă standardul de aur în tratamentul defectelor nervoase, dar alte proceduri, cum ar fi grefele nervoase vascularizate, conductorii nervoși, allogrefele și transferurile nervoase pot fi folosite cu succes în unele cazuri.

Atenția actuală în domeniu se îndreaptă către dezvoltarea de conductori nervoși. Tehnologia textilă reprezintă un domeniu promițător în crearea de conductori nervoși, având în vedere ușurința procesului tehnologic, costurile de producție accesibile și proprietățile mecanice corespunzătoare.

Cuvinte cheie: leziunea nervilor periferici, defect nervos, grefă, conductori nervoși, tehnologia textilă

INTRODUCTION

Peripheral nerve lesions represent a difficult medical problem determining sensitive, motor and associated

psychosocial losses that may deeply and severely impact the quality of life of affected patients [1, 2]. After peripheral nerve lesion, a complex process consisting of degeneration of the entire distal nerve end

as well as degeneration over a short length of the proximal nerve stump occurs [3]. Nerve repair facilitates a unique axonal regeneration pattern that involves generating new distal axons, distal to the lesion site, concomitant with the restoration of original neuronal microstructure through proliferation and migration of all other adjacent cellular components. It is considered that the nerve growth rate after sectioning and repair is approximately 1 to 2 millimetres per day on average [4, 5].

Surgical repair of sectioned peripheral nerves involves microsurgical suture trimmed to healthy stumps, under magnification with magnification loupes or surgical microscope. Correct microsurgical repair is the only method that may ensure functional recovery of the affected segment [5, 6].

The principle of nerve repair is micro-suturing the nerve ends without tension using epineural sutures. If the injury resulted in a nerve defect and a direct suture without tension is not possible, then a structure is needed to fill in the gap. This can be achieved with nerve conduits or grafts. They will act as support for axon regeneration [5, 7].

Autografts are considered the gold standard for nerve gap repair. The grafts are obtained from the same patient, from a different site than the location of the defect. The most common source of nerve grafts is the sural nerve. Autografts provide support for axon regeneration with ideal biocompatibility. The disadvantages of autografts are the need for a donor site that comes with its morbidity and function impairment, the number of available grafts being limited and the difference in nerve thickness between the injured nerve and the graft [8, 9].

Allografts are obtained from a different person and act as a guide for axon regrowth. By using allografts there is no donor site morbidity and a better match in nerve calibre than with autografts, but allografts lead to intense immune reactions. To counter the immune response immunosuppressive treatment is needed which comes with severe adverse reactions, limiting the use of allografts [5, 10].

Nerve conduits have been developed as an alternate strategy in an attempt to overcome the disadvantages of nerve grafts. The ideal nerve conduit needs to be biocompatible and biodegradable, with no immune response, and proper mechanical characteristics such as strength and elasticity and it need to create an ideal environment for nerve regeneration [11–13].

This study aimed to analyse and discuss peripheral nerve lesion cases from our clinic, involving the upper limb, an anatomical segment with highly impactful functional importance. We followed the distribution of nerve lesions, applied therapeutic protocols and attempted to identify potential therapeutic strategies that may optimize functional results.

METHODS

We performed a retrospective analysis of the cases admitted in the Clinic of Plastic Surgery and

Reconstructive Microsurgery of the Clinical Emergency Hospital Bucharest and selected only those who suffered from nerve injuries in the upper limb. The analysis was focused on a period of 3 years, between January 1st, 2017 and December 31st, 2019.

On admission to the hospital, all patients consented to their medical data being used for future research purposes. Variables collected were the date of admission, age, gender, nerves involved, associated acute injuries and the presence of comorbidities. All data were collected and processed using Microsoft Excel, version 16.66.1. The only quantitative variable was the patients' age, for which we calculated the average, the median and the standard deviation.

STUDY RESULTS

We identified 734 patients who suffered from nerve injuries of the upper limb, 156 of which were admitted in 2017 (21.25%), 263 in 2018 (35.83%) and 315 in 2019 (42.91%). Out of the 734 patients included in the study, 600 (81.74%) were male and only 134 (18.26%) were female. The patient distribution based on their age is illustrated in figure 1. The mean age was 45.81 (± 15.23) years and the median age was 46 years. The youngest patient was a 16-year-old male and the oldest was a 94-year-old female.

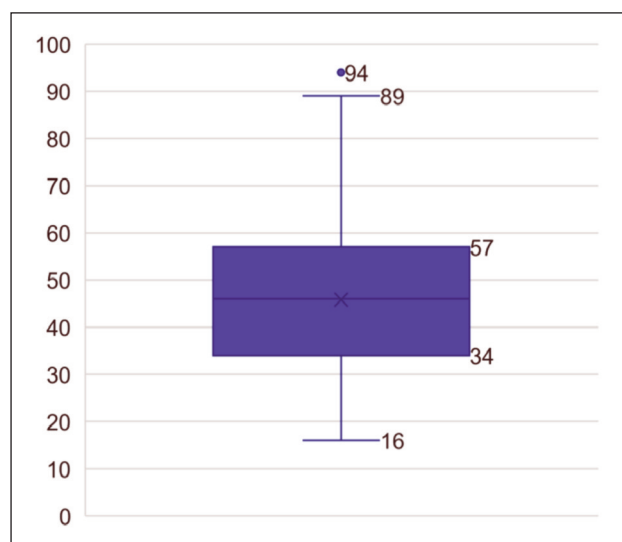


Fig. 1. Patient distribution based on age

The most frequently injured nerves of the upper limb were the digital nerves, adding up to a total of 785 nerves (80.59%), followed by the median nerve (83 nerves; 8.52%), the ulnar nerve (73 nerves; 7.49%), the radial nerve (31 nerves; 3.18%) and, lastly, the musculocutaneous nerve (2 nerves; 0.21%), amounting to a total of 974 injured nerves in the upper limb. The distribution of the injured nerves is illustrated in figure 2.

Some patients had injuries to more than just one nerve, with different combinations arising all presenting in an emergency setting. Hence, the most

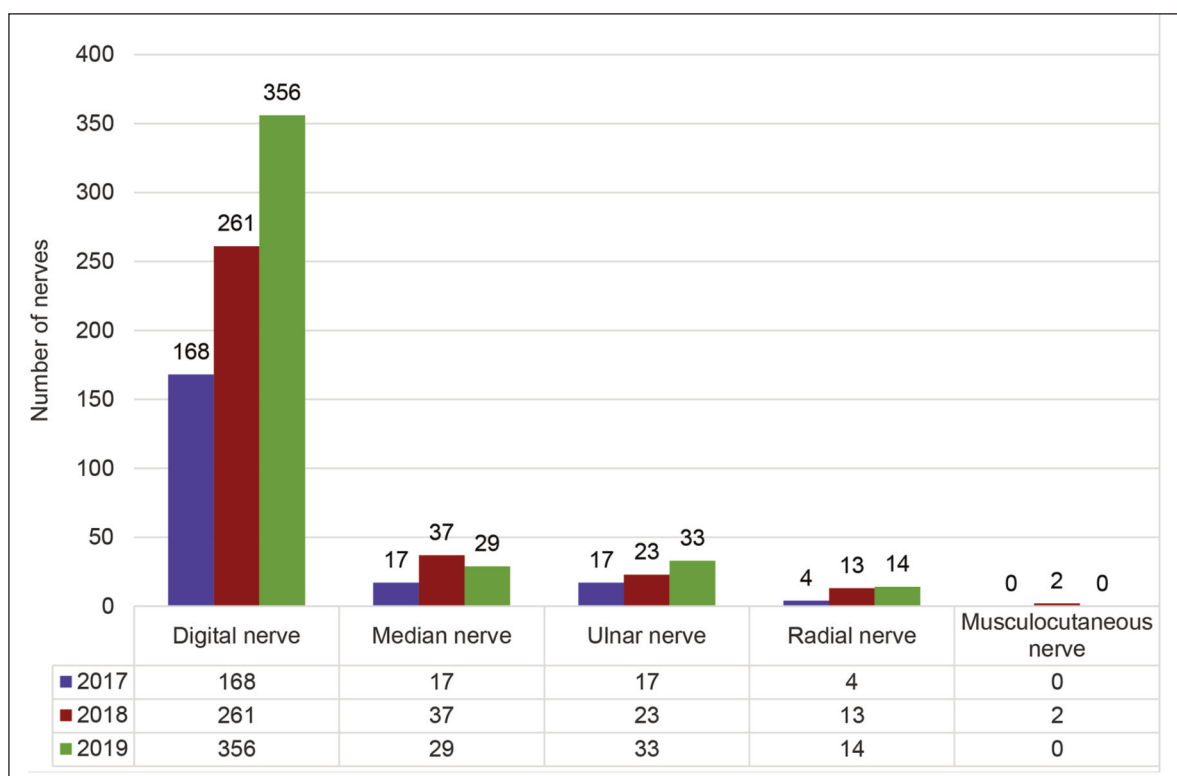


Fig. 2. Yearly distribution of injured nerves

common was an injury to both digital collateral nerves in 27.24% of cases.

Also, associated lesions of large nerves were encountered in our cases (as seen in table 1). The association between the median and the ulnar nerves was encountered in 23 patients (3.13%) presenting to the hospital with trauma to both these nerves. There were 6 patients (0.81%) who had associated injuries in both the median and the radial nerves. The three main nerves in the forearm (median, ulnar and radial nerves) were all damaged in 5 patients (0.68%). We also identified one patient (0.13%) who suffered trauma to the musculocutaneous and radial nerves. Moreover, there was one patient (0.13%) who presented a lower limb injury in addition to the one to the upper limb, thus having injured the radial and the ipsilateral common peroneal nerve.

Table 1

ASSOCIATED LESIONS OF LARGE NERVES	
Type of injured nerves	No. of patients
Median & ulnar	23
Median & radial	6
Median & ulnar & radial	5
Radial & musculocutaneous	1
Radial & common peroneal	1

Of all the 734 patients included in the study, the large majority benefited from the standard nerve repair, which ensures optimal results. However, for some patients, direct neurorrhaphy could not be performed

due to the size of the nerve defects. We identified 42 such cases, most of which involved the digital nerves (24 patients; 57.14% of defects), followed by the ulnar nerve (7 patients; 16.66% of defects), the median nerve (5 patients; 11.90% of defects), the radial nerve (3 patients; 7.14% of defects), both the median and ulnar nerves (2 patients; 4.76% of defects) and, lastly, the posterior interosseous nerve (1 patient; 2.38% of defects). These nerves were injured at different levels, so the reconstructive procedures varied accordingly, as seen in table 2.

Figures 3 and 4 illustrate two of the surgical techniques used for bridging nerve gaps in our patients: Figure 3 displays the use of sural nerve grafts in bridging significant defects of large nerves – radial nerve (figure 3, a and b) and median nerve (figure 3, c and d); figure 4 presents the use of muscle-in-vein autologous conduit for a digital nerve defect of the index finger.

DISCUSSIONS

Traumatic injuries of the upper extremities are a common finding, with a reported incidence varying from 7 to 37/1000 inhabitants/year in Europe for hand injuries. The incidence of nerve injuries is 0.14/1000 inhabitants/year, the most affected being the nerves of the upper extremities [14].

In our clinical study, we observed that there was an inclusion of a large number of patients with peripheral nerve lesions of the upper limb. The majority of the patients are males, with an average age of 46 years, which shows that most of them pertain to the young, professionally active population. This data reveals

RECONSTRUCTIVE PROCEDURES FOR INJURED NERVES AT DIFFERENT LEVELS				
Injured nerve	Level of injury	No. of patients	Reconstructive procedure	No. of procedures
Digital	Digit	19	Spare part nerve graft	6
			Muscle-in-vein conduit	2
			Heterodigital sensate flaps	5
			Nerve transfer from the contralateral non-functional side	6
	Palm	5	Lateral antebrachial cutaneous nerve graft	1
			Spare part nerve graft	3
			Muscle-in-vein conduit	1
Median	Forearm	4	Sural nerve graft	4
	Arm	1	Sural nerve graft	1
Ulnar	Forearm	3	Sural nerve graft	3
	Proximal forearm	4	Ulnar nerve anterior transposition	4
Median+ulnar	Forearm	2	Sural nerve graft	2
Radial	Arm	3	Sural nerve graft	3
Posterior interosseous	Forearm	1	Lateral antebrachial cutaneous nerve graft	1

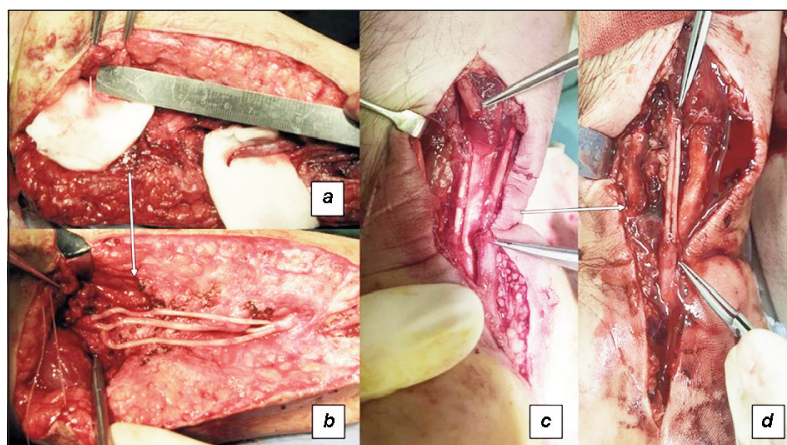


Fig. 3. Sural nerve grafts used for bridging significant defects of large nerves: *a* – radial nerve defect; *b* – sural graft bridging the defect of the radial nerve; *c* – median nerve defect; *d* – sural graft bridging the defect of the median nerve

the importance of peripheral nerve lesions as a public health concern, these patients suffer from mild to severe nerve damage, determining temporary or definitive functional loss, dramatically impacting both the personal quality of life and professional activity. Peripheral nerve lesions are known to have a lengthy recovery, requiring complex surgical interventions, as well as integration into a sustained and efficient rehabilitation program in specialized institutions [15].

The motivation of the patient, the addressability to the physician and medical services, and the existent infrastructure are parameters that impact the functional outcome, with possible precarious results.

Damage to the main nerves of the upper limb leads to difficult and longer recovery, directly proportionate to the proximal site of the lesion [3, 5, 16].

In our clinic, such lesions involving the median, ulnar, radial and musculocutaneous nerves were reported in several 149 patients, representing a fifth of the total patients.

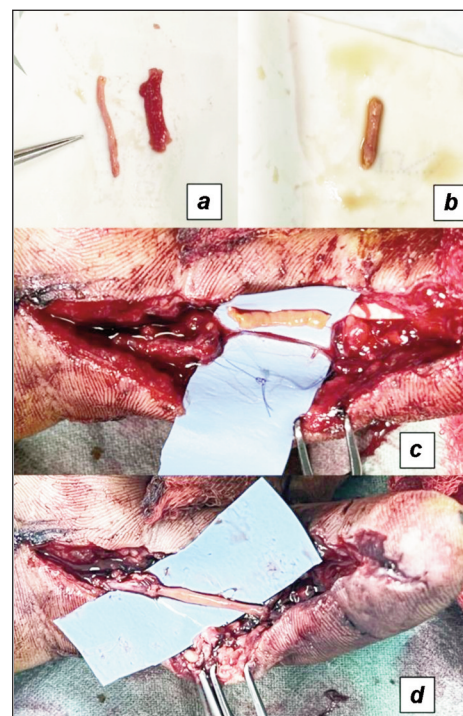


Fig. 4. Muscle-in-vein autologous conduit used for a digital nerve defect of the index finger: *a* – vein (left) and muscle (right) harvested from the anterior aspect of the forearm; *b* – muscle-in-vein conduit; *c* – defect of the digital nerve; *d* – muscle-in-vein conduit bridging the digital nerve defect

Reconstructive options for nerve defects

Direct, primary repair of lesions represents to date the best possible solution for nerve damage. When a nerve cannot be repaired by direct neurorrhaphy,

there are some options that a surgeon must keep in mind, each with its indications and advantages: autologous nerve grafting, vascularized nerve grafting, nerve conduits, allografts and nerve transfers [5, 7, 17]. However, in cases where there is a gap, autologous nerve grafting represents the gold standard. Several nerves can be used as donors, but the sural nerve is the most frequently used due to the ease of dissection and available length [18]. The sural nerve can be a source of roughly 30-40 cm of nerve graft. It has the advantage of low morbidity, leaving denervated only the lateral aspect of the foot, with partial sensitization of the aforementioned area over time [18, 19]. On the other hand, when it comes to nerve defects in the upper limb, harvesting a graft from the lower limb can be regarded as a disadvantage, due to anaesthesia concerns and generating another surgical field.

Often, local options, within the same surgical field can be employed, an example being the medial antebrachial cutaneous nerve, which can provide as much as 20–25 cm of nerve graft. It is a suitable choice for gaps greater than 0.5 cm in the digital nerves. Its posterior branch innervates the skin above the elbow, providing important sensate information about a highly tactile area. This is the reason why it is preferred to use the anterior branch, with lower morbidity resulting in numbness only on the anterior aspect of the forearm. Despite the advantage of having a hidden scar on the medial side of the arm, the donor site may be left with hyperesthesia and dysesthesia [20, 21].

Another local feasible choice that leaves a less important sensory deficit at the donor site is the lateral antebrachial cutaneous nerve because it overlaps with the sensitive branch of the radial nerve. It can provide up to 8-15 cm of nerve graft. A minor concern is that the scar on the volar aspect of the forearm is one that the patient might not consent to as easily [20, 22]. Similarly, the superficial branch of the radial nerve may be used as a donor, but this is reserved only for those cases associating an irreversible injury to the main trunk of the radial nerve or to its cervical roots of origin, cases in which its superficial branch is no longer of use [20].

When harvesting a nerve graft, the surgeon must take into consideration the diameter of the donor's nerve. If the trunk of the donor's nerve is too large, the graft will suffer central necrosis. Hence, vascularized nerve grafting comes as a solution where the nerve is harvested along with its vessels, making it ideal for situations where the recipient bed is heavily devascularized or has suffered extensive fibrosis. The most used vascularized nerve graft is harvested from the ulnar nerve [23–25].

If the patient refuses an autologous nerve graft, or if the case contraindicates it, the next ideal option is nerve conduits. These are used for nerve gaps smaller than 3 cm, so they can provide a pathway through which the axons can regenerate while preventing protrusion of endoneural contents during healing [5, 7, 26, 27]. Veins have been used as nerve autologous conduits, mainly because they are highly acces-

sible within the same surgical field, determining no inflammatory and immunology response and have an inferior donor site morbidity than a nerve graft. Even though vein grafts have acceptable results, the two-point discrimination is slightly inferior but comparable to nerve grafts. They present come to a risk of collapsing when the graft is longer than 1–2 cm, mechanically blocking the axonal regeneration through the vein, needing sometimes to be filled with either muscle, fibrin or textile fibres [28, 29].

Freeze-thawed muscle grafts have also been used as conduits, especially for injuries of cutaneous nerves, but the harvested muscle must be prepared so that the graft becomes acellular. This process leaves intact only the basal membrane, which acts as a promoter for axonal regeneration. Using a composite muscle-in-vein graft as a nerve conduit brings in the advantages of both the vein and the freeze-thawed muscle grafts. With the muscle inserted inside the vein, the conduit can no longer collapse and it has been proved that the myocytes generate growth factors that are beneficial, stimulating Schwann cell regeneration and axonal migration [28, 30, 31].

Nerve transposition, which is frequently used for ulnar nerve lesions of the proximal forearm or elbow, can help compensate for the existing gap between the nerve-sectioned ends. When the proximal nerve stump is not available for adequate repair, a nerve transfer can be performed using a synergistic donor nerve, which is transferred and microsurgically sutured to the distal end of the nerve.

In the presented clinical study, the vast majority of the patients benefited from direct microsurgical repair of the nerve injury. However, we had a series of cases of nerve defects that were repaired using the methods discussed above, with good functional results.

Nerve allografts are the next feasible option, being useful when there is an extensive injury to peripheral nerves, and either the donor sites are not sufficient or the patient refuses such procedures. The advantage is that there is no donor site morbidity whatsoever. Even though host immunosuppression is necessary, it is only temporary, because after the nerve regeneration is completed through the graft, there will be no non-self-cells remaining. Interestingly, it has been shown that short-term immunosuppression has neural regenerative effects. Processed acellular nerve allografts have been developed to avoid the need for immunosuppression, with promising results even in larger nerve gaps (up to 5 cm) [5, 32, 33].

In an attempt to overcome the limitations of nerve grafts, the attention of nerve repair has switched towards nerve conduits. The last decades of research brought to attention new sources of nerve conduits, which aimed to decrease the immunologic response, offer good mechanical quality, speed and enhance the regenerative process, match the efficiency of autologous nerve grafts, while providing the same, results and functional outcomes, through accessible and affordable means. Promising attempts have

been made with collagen, polysaccharides and even synthetic polymers [11, 12, 34–36].

Promising area: the use of textile technologies for bridging nerve defects

Textile technologies have been implicated in the process of making different kinds of materials for implants, stents, and grafts, each having different purposes such as vascular prostheses, intestinal stents, and nerve conduits. Given the fact that the production cost is affordable, the fabrication process is versatile and it offers very good mechanical characteristics the textile conduits are very promising and have generated a lot of interest over time. Textile technologies present advantages over other manufacturing techniques such as 3D printing. The whole process is more facile, takes less time and is more cost-effective [12, 37–40].

Nerve conduit materials

Various materials can be used to manufacture nerve conduits and they can be classified into natural and synthetic polymers. Natural polymers used in nerve repairs are chitosan, collagen, laminin, silk fibroin and alginates, while known usable synthetic materials are silicone polymers, polylactic acid, polyglycolic acid, poly(lactic-co-glycolic acid), polycaprolactone and composites [12, 41, 42].

Natural polymers:

- Chitosan is a linear polysaccharide that resembles the extracellular matrix, with particular mechanical properties. It is biodegradable, non-toxic and promotes nerve regeneration, making it a good material for nerve conduits. It can be used alone or in combination with other natural or synthetic materials and growth factors and offers good results in experimental studies, enhancing axon regeneration [41, 42].
- Collagen is the most important protein in the body, offering structure to human tissues and providing promising results in nerve regeneration. The challenges in using collagen in nerve conduits are its high production cost and poor mechanical resistance [12, 41–44].
- Laminin is a protein from the basal lamina of blood vessels. It promotes axonal regeneration and myelination and can be used to construct nerve conduits. It can be used as a gel to fill other nerve conduits or it can be used in combination with other materials in multi-layered nerve conduits [39, 41].
- Silk fibroin is a protein found in silk, it has good mechanical characteristics, it dissolves slowly and is non-toxic. It is better used in combination with other fibres because silk is friable when used alone. It can be combined with polylactocaprone or poly lactico-glycolic acid to form electrospun nanofibers [12, 30, 45].
- Alginate is found in algae's cells and it has a similar form to connective tissue. It can promote nerve regeneration, has good biocompatibility and is biodegradable making it suitable for nerve conduits. [39, 41]

Synthetic Polymers:

Synthetic materials have been at the centre of nerve conduit development since they can achieve better mechanical and physiological properties than natural materials. There are two kinds of synthetic polymers degradable and non-degradable.

- Silicone polymers have been one of the first materials to be used in nerve conduit manufacture. Silicone conduits have shown some good outcomes, but due to the property of being non-degradable, there is usually a need for a second surgery for removal. If left in place, they can lead to nerve compression syndrome [11, 12, 41].
- Polylactic acid is a biodegradable polymer that can be obtained from natural sources such as potatoes. It is one primary choice when it comes to basic materials because it can be easily designed and moulded into the desired shape and it helps nerve regeneration. The natural course follows metabolism to lactic acid [41].
- Polyglycolic acid can be extracted from pineapple or sugarcane. It is a polyester and degrades to glycolic acid. It is more hydrophilic than polylactic acid and is stabilized by the ester group [41].
- Poly(lactic-co-glycolic acid) is composed of both polylactic and polyglycolic acids. It is more malleable and has better mechanical properties while being less toxic. It degrades slowly, has good biocompatibility and it can be more suitable for nerve conduits [41, 46].
- Polycaprolactone is a polyester, obtained from lactone or hydroxycarboxylic acid. It is degraded to oligolactone, and it takes up to 24 months to be metabolized completely, making it efficient for cases in which the conduit needs very-slow biological integration [41].

Lastly, composite materials can be employed in nerve conduits. The advancement of manufacturing technologies leads to composite materials by mixing different polymers. By mixing different polymers, one can obtain different degrees of degradation and mechanical properties [12, 41].

Textile technologies

Natural and synthetic materials are used to create different kinds of nerve conduits by using different manufacturing techniques such as 3D printing, enzymatic and chemical treatments or textile technologies. The goals and challenges are to develop conduits with the aforementioned and emerging textile materials to obtain the ideal combination of mechanical, structural and biological properties [12, 30, 41, 42].

There are four kinds of manufacturing processes used in obtaining nerve conduits:

- Firstly, the weaving process consists of lacing warp yarn and weft yarn in different patterns specific to different materials. By changing the patterns, and working with different fabrics and arrangements we can achieve different strengths and permeability. This technique offers more in-plane support, offering more strength and flexibility in the same plane as the direction of the fibres, making it less ideal for

a tubular shape structure. The mechanical strength can be enhanced by calibrating the looms and different variables [12].

- Secondly, the knitting process consists of making different kinds of loops and interconnected threads in different planes resulting in different, complex designs that offer strength in both in- and out-plane direction. This manufacturing process is already used in all kinds of medical applications, but the challenge rests in obtaining nerve conduits, which are small in diameter, with the current machines [12, 47].
- Thirdly, the braiding process consists of twisting groups of threads in different patterns. This process can be 2-dimensional or 3-dimensional. The 2-dimensional manufacturing process is used to obtain thin conduits, while the 3-dimensional manufacturing process can only obtain thicker conduits. Besides the thickness, the 2-dimensional process is simpler and more effective and is used to obtain conduits that have better mechanical properties than using the 3-dimensional technique, making it the preferred technique for manufacturing nerve conduits. The braiding process allows more flexibility regarding the design of the conduit, with researchers creating tube-in-tube structures that simulate the nerve bundles or multi-layered structures, each layer with different mechanical and physiological properties [12, 30, 39].
- Electrospinning is a manufacturing process that allows for obtaining very small diameter fibres from polymer solutions by using electric force. This technique can be used to obtain nanofibers that act as an extracellular matrix inside the nerve conduit [12, 48]. Nanofibers can be obtained from different compounds found in the extracellular matrix such as elastin or collagen. The advantage of electrospinning is that it offers freedom in choosing the fabric. Natural materials are preferred over synthetic ones because they offer a better balance between mechanical properties and biocompatibility. The electrospinning technique is used in combination

with various other techniques to manufacture different kinds of multi-layered nerve conduits. The versatility of the electrospinning technique allows the researchers to add different nanoparticles that offer better nerve regeneration such as magnesium or iron oxides [12, 49–52]. Due to the precise synthesis of the nanofibers and the biodegradable properties of various polymers the nanoparticles can be released slowly, continuously and uniformly inside the conduit to help in nerve regeneration [41]. Electrospinning devices are constantly evolving allowing for more powerful nerve conduits.

CONCLUSIONS

Peripheral nerve lesions determine in many cases severe functional deficits, affecting young, active people. Primary nerve repair using microsurgical techniques is attempted as the first therapeutic intention. When a nerve cannot be repaired by direct neurorrhaphy, there are different options for bridging the nerve gap, each with its indications and advantages: autologous nerve grafting-still the gold standard, vascularized nerve grafting, nerve conduits, allografts and nerve transfers. These findings were encountered also in our study group, with a large number of young, working active, predominantly male patients presenting with significant functional impairment determined by upper extremity nerve injuries especially when nerves are affected proximally.

Alternative solutions are currently being explored for bridging nerve gaps to promote better functional recovery in our patient population with affordable resources.

Recently developed nerve conduits made from combinative materials, using modern technologies possess good mechanical properties and biological functions, ensuring the nerve regeneration process. Textile technologies represent a promising field, allowing nerve conduit fabrication with optimal biological properties in a fast and cost-effective manner.

REFERENCES

- [1] Heinzel, J.C., Dadun, L.F., Prahm, C., et al., *Beyond the Knife-Reviewing the Interplay of Psychosocial Factors and Peripheral Nerve Lesions*, In: Journal of Personalized Medicine, 2021, 11, 11, <http://doi.org/10.3390/jpm11111200>
- [2] Wojtkiewicz, D.M., Saunders, J., Domeshek, L., Novak, C.B., Kaskutas, V., Mackinnon, S.E., *Social impact of peripheral nerve injuries*, In: Hand, 2015, 10, 2, 161–167, <http://doi.org/10.1007/s11552-014-9692-0>
- [3] Menorca, R.M., Fussell, T.S., Elfar, J.C., *Nerve physiology: mechanisms of injury and recovery*, In: Hand Clinics, 2013, 29, 3, 317–330, <http://doi.org/10.1016/j.hcl.2013.04.002>
- [4] Sulaiman, W., Gordon, T., *Neurobiology of peripheral nerve injury, regeneration, and functional recovery: from bench top research to bedside application*, In: Ochsner Journal, 2013, 13, 1, 100–108
- [5] Grinsell, D., Keating, C.P., *Peripheral nerve reconstruction after injury: a review of clinical and experimental therapies*, In: Biomed Research International, 2014, 2014, 698256, <http://doi.org/10.1155/2014/698256>
- [6] Hems, T., *Operating on nerves: Surgical approaches, primary and secondary repair, nerve grafting and nerve transfer*, In: Living Textbook of Hand Surgery, 2014, <http://doi.org/10.5680/lhhs000025>
- [7] Griffin, M.F., Malahias, M., Hindocha, S., Khan, W.S., *Peripheral nerve injury: principles for repair and regeneration*, In: The Open Orthopaedics Journal, 2014, 8, 1, 199–203, <http://doi.org/10.2174/1874325001408010199>
- [8] Hoben, G.M., Ee, X., Schellhardt, L., et al., *Increasing Nerve Autograft Length Increases Senescence and Reduces Regeneration*, In: Plastic and Reconstructive Surgery, 2018, 142, 4, 952–961, <http://doi.org/10.1097/PRS.0000000000004759>

- [9] Tada, K., Nakada, M., Matsuta, M., Yamauchi, D., Ikeda, K., Tsuchiya, H., *Long-Term Outcomes of Donor Site Morbidity After Sural Nerve Graft Harvesting*, In: Journal of Hand Surgery Global Online, 2020, 2, 2, 74–76, <http://doi.org/10.1016/j.jhsg.2020.01.001>
- [10] Bittner, G.D., Bushman, J.S., Ghergherehchi, C.L., et al., *Typical and atypical properties of peripheral nerve allografts enable novel strategies to repair segmental-loss injuries*, In: Journal of Neuroinflammation, 2022, 19, <http://doi.org/10.1186/s12974-022-02395-0>
- [11] Nectow, A.R., Marra, K.G., Kaplan, D.L., *Biomaterials for the development of peripheral nerve guidance conduits*, In: Tissue Engineering Part B: Reviews, 2012, 18, 1, 40–50, <http://doi.org/10.1089/ten.TEB.2011.0240>
- [12] Yan, Y., Yao, R., Zhao, J., et al., *Implantable nerve guidance conduits: Material combinations, multi-functional strategies and advanced engineering innovations*, In: Bioactive Materials, 2021, 11, 57–76, <http://doi.org/10.1016/j.bioactmat.2021.09.030>
- [13] Fornasari, B.E., Carta, G., Gambarotta, G., Raimondo, S., *Natural-Based Biomaterials for Peripheral Nerve Injury Repair*, In: Frontiers in Bioengineering and Biotechnology, 2020, 8, 554257, <http://doi.org/10.3389/fbioe.2020.554257>
- [14] Dahlin, L.B., Wiberg, M., *Nerve injuries of the upper extremity and hand*, In: EFORT Open Reviews, 2017, 2, 5, 158–170, <http://doi.org/10.1302/2058-5241.2.160071>
- [15] Lopes, B., Sousa, P., Alvites, R., et al., *Peripheral Nerve Injury Treatments and Advances: One Health Perspective*, In: International Journal of Molecular Science, 2022, 23, 2, 918, <http://doi.org/10.3390/ijms23020918>
- [16] Wang, M.L., Rivlin, M., Graham, J.G., Beredjiklian, P.K., *Peripheral nerve injury, scarring, and recovery*, In: Connective Tissue Research, 2019, 60, 1, 3–9, <http://doi.org/10.1080/03008207.2018.1489381>
- [17] Ray, W.Z., Mackinnon, S.E., *Management of nerve gaps: autografts, allografts, nerve transfers, and end-to-side neurorrhaphy*, In: Experimental Neurology, 2010, 223, 1, 77–85, <http://doi.org/10.1016/j.expneurol.2009.03.031>
- [18] Piedra Buena, I.T., Fichman, M., *Sural Nerve Graft*, In: StatPearls [Internet], 2022, <https://www.ncbi.nlm.nih.gov/books/NBK557715/>
- [19] Bamba, R., Loewenstein, S.N., Adkinson, J.M., *Donor site morbidity after sural nerve grafting: A systematic review*, In: Journal of Plastic, Reconstructive & Aesthetic Surgery, 2021, 74, 11, 3055–3060, <http://doi.org/10.1016/j.bjps.2021.03.096>
- [20] Poppler, L.H., Davidge, K., Lu, J.C., Armstrong, J., Fox, I.K., Mackinnon, S.E., *Alternatives to sural nerve grafts in the upper extremity*, In: Hand, 2015, 10, 1, 68–75, <http://doi.org/10.1007/s11552-014-9699-6>
- [21] Li, H., Zhu, W., Wu, S., Wei, Z., Yang, S., *Anatomical analysis of antebrachial cutaneous nerve distribution pattern and its clinical implications for sensory reconstruction*, In: PLOS One, 2019, 14, 9, <http://doi.org/10.1371/journal.pone.0222335>
- [22] Unal, M.B., Gokkus, K., Sirin, E., Cansü, E., *Lateral Antebrachial Cutaneous Nerve as a Donor Source for Digital Nerve Grafting: A Concept Revisited*, In: The Open Orthopaedics Journal, 2017, 11, 1041–1048, <http://doi.org/10.2174/1874325001711011041>
- [23] Isaacs, J., Safa, B., *A Preliminary Assessment of the Utility of Large-Caliber Processed Nerve Allografts for the Repair of Upper Extremity Nerve Injuries*, In: Hand, 2017, 12, 1, 55–59, <http://doi.org/10.1177/1558944716646782>
- [24] Broeren, B.O., Duraku, L.S., Hundepool, C.A., et al., *Nerve recovery from treatment with a vascularized nerve graft compared to an autologous non-vascularized nerve graft in animal models: A systematic review and meta-analysis*, In: PLOS One, 2021, 16, 12, <http://doi.org/10.1371/journal.pone.0252250>
- [25] Terzis, J.K., Kostopoulos, V.K., *Vascularized nerve grafts and vascularized fascia for upper extremity nerve reconstruction*, In: Hand, 2010, 5, 1, 19–30, <http://doi.org/10.1007/s11552-009-9189-4>
- [26] Muheremu, A., Ao, Q., *Past, Present, and Future of Nerve Conduits in the Treatment of Peripheral Nerve Injury*, In: Biomed Research International, 2015, 2015, 237507, <http://doi.org/10.1155/2015/237507>
- [27] Deal, D.N., Griffin, J.W., Hogan, M.V., *Nerve conduits for nerve repair or reconstruction*, In: Journal of the American Academy of Orthopaedic Surgeons, 2012, 20, 2, 63–68, <http://doi.org/10.5435/JAAOS-20-02-063>
- [28] Heinzel, J.C., Quyen Nguyen, M., Kefalianakis, L., et al., *A systematic review and meta-analysis of studies comparing muscle-in-vein conduits with autologous nerve grafts for nerve reconstruction*, In: Scientific Reports, 2021, 11, 1, <http://doi.org/10.1038/s41598-021-90956-3>
- [29] Sabongi, R.G., Fernandes, M., Dos Santos, J.B., *Peripheral nerve regeneration with conduits: use of vein tubes*, In: Neural Regeneration Research, 2015, 10, 4, 529–533, <http://doi.org/10.4103/1673-5374.155428>
- [30] Houshyar, S., Bhattacharyya, A., Shanks, R., *Peripheral Nerve Conduit: Materials and Structures*, In: ACS Chemical Neuroscience, 2019, 10, 8, 3349–3365, <http://doi.org/10.1021/acschemneuro.9b00203>
- [31] Kornfeld, T., Vogt, P.M., Radtke, C., *Nerve grafting for peripheral nerve injuries with extended defect sizes. Nervenrekonstruktion für periphere Nervenverletzungen ausgedehnter Defektgrößen*, In: Wiener Medizinische Wochenschrift, 2019, 169, 9–10, 240–251, <http://doi.org/10.1007/s10354-018-0675-6>
- [32] Brooks, D.N., Weber, R.V., Chao, J.D., et al., *Processed nerve allografts for peripheral nerve reconstruction: a multicenter study of utilization and outcomes in sensory, mixed, and motor nerve reconstructions*, In: Microsurgery, 2012, 32, 1, 1–14, <http://doi.org/10.1002/micr.20975>
- [33] Safa, B., Jain, S., Desai, M.J., et al., *Peripheral nerve repair throughout the body with processed nerve allografts: Results from a large multicenter study*, In: Microsurgery, 2020, 40, 5, 527–537, <http://doi.org/10.1002/micr.30574>

- [34] Rebowe, R., Rogers, A., Yang, X., Kundu, S.C., Smith, T.L., Li, Z., *Nerve Repair with Nerve Conduits: Problems, Solutions, and Future Directions*, In: Journal of Hand and Microsurgery, 2018, 10, 2, 61–65, <http://doi.org/10.1055/s-0038-1626687>
- [35] Isaacs, J., Browne, T., *Overcoming short gaps in peripheral nerve repair: conduits and human acellular nerve allograft*, In: Hand, 2014, 9, 2, 131–137, <http://doi.org/10.1007/s11552-014-9601-6>
- [36] Carvalho, C.R., Oliveira, J.M., Reis, R.L., *Modern Trends for Peripheral Nerve Repair and Regeneration: Beyond the Hollow Nerve Guidance Conduit*, In: Frontiers in Bioengineering and Biotechnology, 2019, 7, 337, <http://doi.org/10.3389/fbioe.2019.00337>
- [37] Singh, C., Wong, C.S., Wang, X., *Medical Textiles as Vascular Implants and Their Success to Mimic Natural Arteries*, In: Journal of Functional Biomaterials, 2015, 6, 3, 500–525, <http://doi.org/10.3390/jfb6030500>
- [38] Doersam, A., Tsigkou, O., Jones, C., *A Review: Textile Technologies for Single and Multi-Layer Tubular Soft Tissue Engineering*, In: Advanced Materials Technology, 2022, 2101720, <http://doi.org/10.1002/admt.202101720>
- [39] Arslantunali, D., Dursun, T., Yucel, D., Hasirci, N., Hasirci, V., *Peripheral nerve conduits: technology update*, In: Medical Devices (Auckland, N.Z.), 2014, 7, 405–424, <http://doi.org/10.2147/MDER.S59124>
- [40] Kang, N.U., Lee, S.J., Gwak, S.J., *Fabrication Techniques of Nerve Guidance Conduits for Nerve Regeneration*, In: Yonsei Medical Journal, 2022, 63, 2, 114–123, <http://doi.org/10.3349/ymj.2022.63.2.114>
- [41] Zhang, M., Li, C., Zhou, L.P., Pi, W., Zhang, P.X., *Polymer Scaffolds for Biomedical Applications in Peripheral Nerve Reconstruction*, In: Molecules, 2021, 26, 9, <http://doi.org/10.3390/molecules26092712>
- [42] Fornasari, B.E., Carta, G., Gambarotta, G., Raimondo, S., *Natural-Based Biomaterials for Peripheral Nerve Injury Repair*, In: Frontiers in Bioengineering and Biotechnology, 2020, 8, 554257, <http://doi.org/10.3389/fbioe.2020.554257>
- [43] Dong, C., Lv, Y., *Application of Collagen Scaffold in Tissue Engineering: Recent Advances and New Perspectives*, In: Polymers, 2016, 8, 2, <http://doi.org/10.3390/polym8020042>
- [44] Li, X., Zhang, X., Hao, M., et al., *The application of collagen in the repair of peripheral nerve defect*, In: Frontiers in Bioengineering and Biotechnology, 2022, 10, 973301, <http://doi.org/10.3389/fbioe.2022.973301>
- [45] Nguyen, T.P., Nguyen, Q.V., Nguyen, V.H., et al., *Silk Fibroin-Based Biomaterials for Biomedical Applications: A Review*, In: Polymers, 2019, 11, 12, <http://doi.org/10.3390/polym11121933>
- [46] Yu, T., Zhao, C., Li, P., Liu, G., Luo, M., *Poly(lactic-co-glycolic acid) conduit for repair of injured sciatic nerve: A mechanical analysis*, In: Neural Regeneration Research, 2013, 8, 21, 1966–1973, <http://doi.org/10.3969/j.issn.1673-5374.2013.21.005>
- [47] Zhang, X., Ma, P., *Application of Knitting Structure Textiles in Medical Areas*, In: Autex Research Journal, 2018, 18, 2, 181–191, <http://doi.org/10.1515/aut-2017-0019>
- [48] Xue, J., Wu, T., Dai, Y., Xia, Y., *Electrospinning and Electrospun Nanofibers: Methods, Materials, and Applications*, In: Chemical Reviews, 2019, 119, 8, 5298–5415, <http://doi.org/10.1021/acs.chemrev.8b00593>
- [49] Xie, J., MacEwan, M.R., Liu, W., et al., *Nerve guidance conduits based on double-layered scaffolds of electrospun nanofibers for repairing the peripheral nervous system*, In: ACS Applied Materials & Interfaces, 2014, 6, 12, 9472–9480, <http://doi.org/10.1021/am5018557>
- [50] Yan, B., Zhang, Y., Li, Z., Zhou, P., Mao, Y., *Electrospun nanofibrous membrane for biomedical application*, In: SN Applied Sciences, 2022, 4, 6, <http://doi.org/10.1007/s42452-022-05056-2>
- [51] Behtaj, S., Ekberg, J.A.K., St John, J.A., *Advances in Electrospun Nerve Guidance Conduits for Engineering Neural Regeneration*, In: Pharmaceutics, 2022, 14, 2, <http://doi.org/10.3390/pharmaceutics14020219>
- [52] Pala, I.E., Kaya, Ç.P., *Textile fibres in product design*, In: Industria Textila, 2021, 72, 3, 340–345, <http://doi.org/10.35530/IT.072.03.1673>

Authors:

CRISTIAN VLADIMIR VANCEA¹, ANDREEA GROSU-BULARDA¹, ANDREI CRETU¹, FLORIN-VLAD HODEA¹, KHALID AL-FALAH^{1,2}, ALEXANDRU STOIAN¹, ALEXANDRU LAURENTIU CHIOTOROIU^{2,3}, CARMEN MIHAI⁴, CRISTIAN SORIN HARIGA^{1,2}, IOAN LASCĂR^{1,2}, RĂZVAN NICOLAE TEODOREANU^{1,2}

¹Clinic of Plastic Surgery, Aesthetic and Reconstructive Microsurgery,
Clinical Emergency Hospital Bucharest, Romania

²UMF Carol Davila Bucharest, Romania

³General Surgery Clinic, Clinical Emergency Hospital Bucharest, Romania

⁴National Research and Development Institute for Textiles and Leather, Bucharest, Romania

Corresponding author:

ANDREEA GROSU-BULARDA, MD, PhD
e-mail: andreeabularda@gmail.com